

Penelope

03

AGE 64

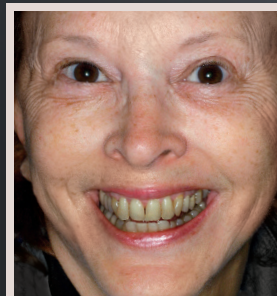
OCCUPATION Retired

SMILE CONCERNS

Age-related discoloration, crowding, defective crowns

FIXED THEM WITH

Ceramic crowns and contouring



BEFORE



AFTER


THE SMILE MAKEOVER

A WHITER SMILE

To help Penelope achieve the bright smile she wanted, Atlanta cosmetic dentist Ronald E. Goldstein, DDS, used a restorative approach. The lower teeth were cosmetically contoured, in-office bleaching treatments lightened her lower teeth and composite resin restored some of the upper posterior teeth. "Ten all-ceramic crowns helped brighten her teeth and restore a younger-looking smile," says Dr. Goldstein.

"Discoloration was making my upper teeth rather unattractive. The decision to get a smile makeover was easy. Immediately after, acquaintances and friends complimented me."

MORE >



BEFORE



AFTER

AGE 25

OCCUPATION

Aspiring actress

SMILE CONCERNS

Gummy smile, short and worn irregular front teeth and spaces between teeth

FIXED THEM WITH

Veneers and gum recontouring

02 Alyssa

"I always had tiny teeth and was uncomfortable with my smile. When I finished high school, I started pursuing acting and participating in pageants but I was still hiding behind my smile. Now I can't stop smiling and I feel more confident."

THE SMILE MAKEOVER

LUMINOUS SMILE

Apple Valley, MN, cosmetic dentist Fred Hermanson, DDS, says, "Alyssa's smile was ineffective in that it did not project the image of sophistication that was consistent with her desires." After an initial consultation with her, a diagnostic preview of the proposed smile makeover was created. Once Alyssa approved the proposed result, treatment began. To address her gummy smile, the gum tissue was recontoured using a soft tissue laser, which can cause minimal discomfort. But, Dr. Hermanson explains, "the reward is immediate—the teeth appear larger instantly." Alyssa's teeth were later prepared for 10 porcelain veneers. After another two weeks, the final veneers were tried on for evaluation and patient approval before being bonded to the teeth.